

Human Digestive System Anatomy

Objectives:

1. Learn the anatomy of the digestive system. You should be able to find all terms in bold on the human torso models.
2. Relate structure of the system to some of its functions.

I. Introduction:

Some terms used to describe the relative positions of body parts are used repeatedly throughout the lab, and appear in a glossary at the end of this exercise.

II. a. EXTERNAL ANATOMY

The trunk of mammals is divided into a **thorax**, which is bordered by **ribs**, and an **abdomen**. Most of the digestive system is within the abdomen, but the head, neck, and thorax contain the superior end of the digestive system.

II. b. DIGESTIVE SYSTEM

The digestive system includes the alimentary canal or gastrointestinal tract, a tubular, muscle-lined passageway that extends from the mouth to the anus. The muscles in the walls of the passage way are responsible for peristalsis. You will view the regions along this tube that are specialized for various activities of the digestive system.

Path of Air

Since the paths of air and food are closely associated, let's also trace the path of air through the head and neck. When the mouth is closed, air enters the body through the **external nares or nostrils**. The external nares lead to a chamber dorsal to the hard palate, called the **nasal cavity**.

Air then passes from the nasal cavity to the **nasopharynx**, which is a chamber dorsal to the soft palate. Only mammals have a hard palate, which separates the breathing and eating passageways. This allows mammals to chew food and breathe at the same time. Only mammals truly chew their food and have teeth specialized for chewing. After air enters the glottis, it proceeds through the larynx and trachea to the lungs.

Path of Food

The head and neck contain the **mouth, oral cavity, and pharynx**.

Food enters the **oral cavity** through the **mouth**, which is bounded by the lips. The roof of the oral cavity is formed by a bony palate, the **hard palate**. At the posterior end of the hard palate the bone ends and the roof of the mouth becomes soft, i.e. the **soft palate**. (The difference in texture is not notable on the models, but bone is modeled in the hard palate.) The oral cavity is that part of the digestive tract from the lips to the end of the hard palate.

Digestion begins in the oral cavity, as digestive enzymes such as amylases secreted in saliva, are mixed with the food during chewing. Amylase catalyzes the breakdown of amylose, or starch, into simpler carbohydrates.

The tongue pushes food from the oral cavity into the region ventral to the soft palate, which is called the **oropharynx**. Projecting into the oropharynx is a flap, the **epiglottis**, which partially surrounds an opening at its base, called the **glottis**. The glottis eventually leads to the lungs. Note the two openings in the pharynx. One goes to the trachea, which is always open due to its rings of cartilage, and the other opening is to the **esophagus**.

When food enters the oropharynx, a reflex makes the epiglottis fold back, closing the glottis and allowing food to slide into the esophagus. Once in the esophagus, peristaltic contractions of the esophagus push the food to the stomach. No digestion occurs in the esophagus. It is just a passageway that connects the pharynx to the stomach.

Abdominal Region

The abdomen is the area inferior to the ribs that contains most of the digestive, reproductive, and excretory organs, collectively known as the **viscera**.

The cavity in the abdomen that contains the viscera is the **peritoneal cavity**, which together with the thoracic cavity constitutes the **coelom**. The **diaphragm**, a muscle that aids in inhalation, forms a partition between the thoracic and abdominal cavities.

Pressed against the inferior side of the diaphragm on the right side of the abdominal cavity is the dark brown **liver**. Its color is due to its rich blood supply. The liver has a variety of functions, including the production of bile, which aids in the emulsification of fats. Bile is stored temporarily in the **gall bladder**, a greenish sac embedded in the posterior face of the liver.

Find the **spleen**, which is a fist-shaped, brown organ on the left side of the abdominal cavity that superficially resembles the liver in color, due to a rich supply of blood. The **spleen** functions in the storage, destruction, and production of red blood cells. The spleen is not part of the digestive system, but is mentioned here because students always ask about it.

Inferior to the diaphragm on the left side of the abdominal cavity is the sac-like **stomach**. Locate the **cardiac** end of the stomach near the diaphragm where the esophagus enters the stomach. It is named the 'cardiac end' because it is the end closest to the heart. There is a weak muscle here called the **cardiac sphincter** that keeps food in the stomach from splashing on to the esophagus. The stomach walls secrete HCl as well as pepsin, an enzyme that catalyzes the breakdown of some proteins.

What would be the result of the contents of the stomach splashing onto the esophagus? (There's a common name for this occurrence.)

At the posterior end of the stomach is a constriction where the stomach joins the anterior end of the small intestine. This constriction between the stomach and small intestine is the **pyloric sphincter**, which is a circular muscle (a sphincter) that controls the movement of acidic chyme from the stomach to the small intestine. It allows just a little bit of stomach contents to move into the small intestine at a time. As the stomach's peristaltic waves push food from the cardiac end to the pyloric end, the pyloric sphincter will open and let a bit of partially digested food into the small intestine.

What is different about the stomach contents that makes it important to have gate-like muscles at either end of the stomach?

The anterior end of the small intestine is the **duodenum** – so named because it is about 12 inches long in the average human. (Latin for twelve is 'duodecim.') The small intestine on the model is not loose as it is in real life. In a living person it is actually a tube about 3 meters long. The duodenum begins at the pylorus of the stomach, extends to the right side of the abdomen, then loops back to the left half of the body, passing close to the stomach and spleen.

Accessory organs – these are not part of the alimentary canal, but are important organs for digestion.

Inferior to the stomach and posterior to the small intestine is the **pancreas**. The pancreas is a long, irregularly-shaped gland, with superficial resemblance to cottage cheese. Some of its products, like the hormones insulin and glucagon, are dumped into the blood as they are needed. (Thus, the pancreas is an endocrine gland.) The pancreas also produces enzymes that catalyze protein digestion. These enzymes which are released as needed into the duodenum through a duct. Thus, the pancreas is also an exocrine gland.

Bile produced in the liver also empties into the duodenum. Ducts from the liver and gall bladder join to form the **common bile duct** which enters the anterior side of the

duodenum right next to the pylorus. Bile emulsifies fats, and the digestion of fats does not begin until they reach the small intestine.

The small intestine loops back and forth, and fills much of the abdominal cavity. The small intestine is held in place by fan-like folds of connective tissue (**mesentery**) that contain many blood vessels. Why would so many blood vessels be attach to the small intestine? (Think about the major reason we have a digestive system) _____

Find where the small intestine is attached to the large intestine and you will find 3-way junction with the **colon** (a.k.a. **large intestine**). A dead end tube or sac, the **caecum**, will be on one side of the junction. The colon is on the other side (the small intestine is, of course, the third). In humans there is a relatively short caecum off of which an even thinner extension is found This dead end tube, about as big around as a pencil and a couple of inches long, is the _____.

The colon has three regions, each named for its orientation. Within the ascending colon material moves upward. Within the transverse colon material moves from right to left, and within the descending colon, material moves inferiorly toward the rectum.

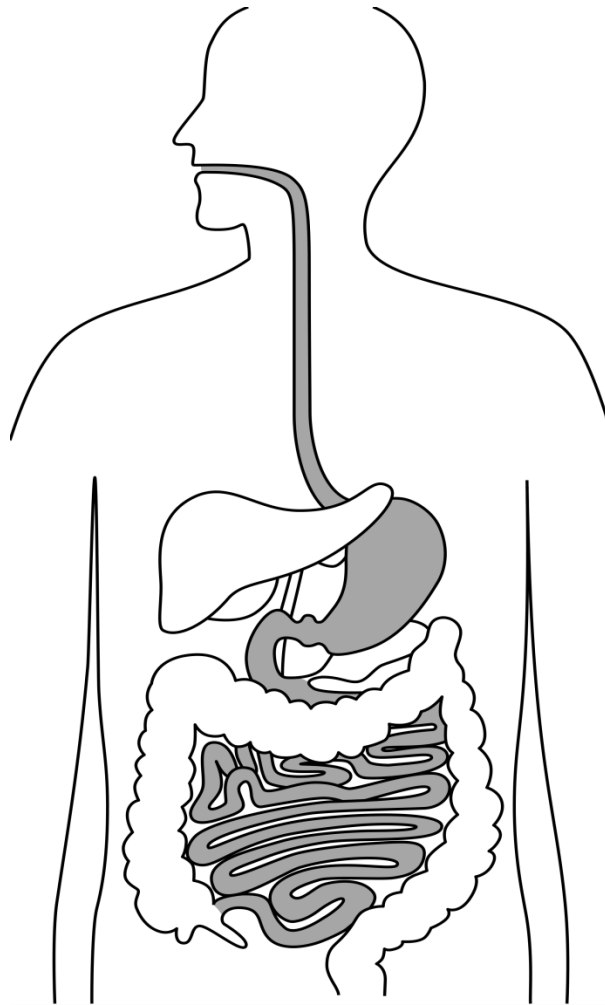
The distal portion of the colon extends into the true pelvis, which is the cylinder surrounded by bone in the center of the pelvis. The colon ends at the sigmoid colon and then the **rectum**. The external opening of the rectum is the anus. (Sigmoid means “similar to sigma” or “similar to the letter S” as that part of the colon makes a few zig-zags on its way to the rectum.)

Let’s review the passage of food through the alimentary tract: If you swallow a piece of gum that you don’t digest, list all the organs, in order, that the gum passes through:

Mouth → _____

_____ → anus

IDENTIFY the following structures in the human torso model on the attached drawing: esophagus, liver, stomach, cardiac end of stomach, pyloric end of stomach, duodenum, pancreas, common bile duct, ascending colon, transverse colon, descending colon, caecum, vermiform appendix, and rectum.



GLOSSARY OF FREQUENTLY USED ANATOMICAL TERMS

A number of terms will be used quite frequently in the dissection exercises. These terms are used to describe the location of parts on the organism.

Some of these terms (anterior, distal, dorsal, lateral, medial, posterior, proximal, and ventral) are often used relatively. For example, if we say that the diaphragm is anterior to the stomach, it does not mean that you will find the diaphragm at the anterior end of the organism. It means that, once you find the stomach, you will find the diaphragm on the anterior side of the stomach, i.e. the side closest to the anterior end of the animal.

anterior -- the head end of an animal, or in that direction. (e.g. on the pig, the front legs are anterior to the umbilical cord.)

cross section (c.s., t.s., x.s.) -- cut at right angles to the long axis of a structure or organism.

distal -- the part of an organ or limb that is furthest from the origin or point of attachment. (E.g. the fingers are distal to the wrist.)

dorsal -- the back or upper side of an animal, or in that direction. (e.g. the vertebral column is dorsal to the heart.)

lateral -- the side, or toward the side.

left -- the organism's left.

longitudinal section -- a cut along the long axis of a structure or organism.
May be either a frontal or sagittal section.

medial or median -- on or toward the midline of the organism.

posterior -- the tail end of an animal, or in that direction.

proximal -- the part of an organ or limb that is nearest the origin or point of attachment. (the wrist is proximal to the fingers)

right -- the organism's right.

ventral -- the underside of an animal, or in that direction. (e.g. the heart is ventral to the vertebral column.)